



3346 Lennon Road
Flint, Michigan 48507

LOCATIONS

Flint
3346 Lennon Road

Fenton
221 W. Roberts Street

Grand Blanc
8483 Holly Road

Villa Linda
5059 Villa Linda Pkwy • Suite 25

Davison
1141 S. State Road

Scheduling: (810) 732-1919

Billing: (810) 244-3871

Medical Records: (810) 732-1846

Pre-Registration: (810) 244-7100



rmipc.net
(810) 732-1919

RMI offers evening and

weekend appointment times

to fit your patient's schedule.

We know you have a choice

in imaging partners.

Thanks for choosing RMI.

Clearly. Better. Choice.

RMI SERVICES AND LOCATIONS

SERVICE

SITE(S) OFFERED*

Bone Densitometry (DEXA)	L F C D
Breast Specific Gamma Imaging	L
Computed Tomography (CT)	L F C
Cryoblation	L
Digital Mammography	L F C V D
Fluoroscopy	L F C
Interventional Radiology	L
Magnetic Resonance Imaging (MRI)	L
MRI Guided Breast Biopsy	L
Nuclear Medicine	L F C
PET/CT	L
Stereotactic Guided Breast Biopsy	L
Ultrasound	L F C V D
Vascular Imaging	L F C V D
X-Ray	L F C V D
4-D Breast MRI	L
* SITE(S)	
L	Lennon Road (Flint)
F	Fenton
C	Grand Blanc
V	Villa Linda
D	Davison

REGIONAL MEDICAL IMAGING Inside View

RMI follows Fleischner Society guidelines for monitoring patients with small pulmonary nodules

INSIDE THIS ISSUE:

RMI follows Fleischner Society Guidelinespg 1

PET/CT for Early Diagnosis of Alzheimer's.....pg 2

Options for Renal Artery Stenosispg 2

Community Breast Conferencepg 3

Meet Steve Galliwaypg 3

Medicaid Accepted.....pg 3

Services and Locations.....pg 4

Q - When a CT scan ordered for reasons other than suspected cancer detects small lung nodules (<4mm) as an incidental finding, it creates a dilemma for physicians. Even in smokers, over 99 percent of these nodules do not develop into malignancies. How aggressively should we monitor these patients, bearing in mind the potential negative effects of unnecessary scans—and possibly even surgeries—resulting from false positives?

A - This issue was addressed nearly six years ago by the Fleischner Society, a multidisciplinary medical society for thoracic radiology, in guidelines based on the latest research available at the time. Like nearly 60 percent of radiologists surveyed in a followup study published last year in the journal *Radiology*, RMI endorses and follows these guidelines.

However, significant variations remain, with some physicians continuing to favor the earlier practice of considering all noncalcified pulmonary nodules as potentially malignant until they have shown stability through 4–5 followup CT examinations over a two-year period. RMI, however, concurs with the authors of the Fleischner Society guidelines that the followup protocol should vary depending on nodule size and the patient’s cancer risk factors, such as age, smoking history, previous cancer history, or known primary cancer.

The chart below summarizes the protocol RMI follows.

Nodule Size (mm)*	Low-Risk Patient †	High-Risk Patient ‡
≤4	No followup	Followup CT at 12 mo; if unchanged, no further followup [¶]
>4–6	Followup CT at 12 mo; if unchanged, no further followup	Initial followup CT at 6–12 mo then at 18–24 mo if no change [¶]
>6–8	Initial followup CT at 6–12 mo then at 18–24 mo if no change	Initial followup CT at 3–6 mo then at 9–12 and 24 mo if no change
>8	Followup CT at around 3, 9, and 24 mo, dynamic contrast-enhanced CT, PET, and/or biopsy	Same as for low-risk patient

SOURCE: MacMahon, Austin, Gamsu et al., 398.

*Average of length and width.

†Minimal or absent history of smoking or of other known risk factors.

‡History of smoking or of other known risk factors.

¶Nonsolid (ground-glass opacity) or partly solid nodules may require longer follow-up to exclude indolent adenocarcinoma.

If you have questions about this protocol or have a specific case you would like to discuss, please contact Jeffrey Mitchinson, M.D., at **(810) 732-1919**.

REFERENCES

Eisenberg RL, Bankier AA, Boiselle PM. “Compliance with Fleischner Society guidelines for management of small lung nodules: A survey of 834 radiologists.” *Radiology* 2010 255(1):218-224.

MacMahon H, Austin JHM, Gamsu G, et al. “Guidelines for management of small pulmonary nodules detected on CT scans: A statement from the Fleischner Society.” *Radiology* 2005 237(2):395-400.



Clearly. Better. Choice.

rmipc.net
(810) 732-1919

Early Diagnosis with PET/CT Can Make Drug Therapy for Alzheimer's More Effective

Medicare Guidelines Allow Scans Even When Symptoms are Early and Mild

Several drug classes, including cholinesterase inhibitors and glutamate regulators, can help Alzheimer's patients function longer at a higher level. The sooner therapy begins, the better the outcome is likely to be.

When patients show early evidence of cognitive changes, it can be difficult to differentiate Alzheimer's from other dementias, including those for which Alzheimer's drugs are inappropriate or contraindicated.

"If you observe the patient for six to twelve months and see the characteristic progression of Alzheimer's, there's little doubt about the diagnosis," said Larry McNamee, M.D., Medical Director for PET/CT. "Waiting costs the patient precious time."

PET/CT can be a powerful tool for early diagnosis. Dr. McNamee interprets PET/CT brain studies with the assistance of MIMneuro software, a product that he helped develop. MIMneuro compares a patient's study with a model of a "normal" brain for the patient's age group, derived from numerous imaging studies of patients without dementia symptoms.

"Even if a patient presents with very early and mild symptoms, a PET/CT interpreted with the help of MIMneuro can differentiate Alzheimer's from other dementias, such as frontotemporal dementia or dementia with Lewy bodies," said Dr. McNamee. "If the impression is Alzheimer's, the family doctor can prescribe medications with confidence—early enough to make a difference."

Medicare guidelines allow PET/CT exams for patients in certain scenarios that may indicate pre-dementia or early-stage Alzheimer's, including an abnormal score on the Mini Mental State Examination (MMSE) along with tests to rule out other possible causes, such as thyroid disorders or vascular issues. To consult with a radiologist about a patient experiencing cognitive changes, contact RMI at **(810) 732-1919**.

For suspected renal artery stenosis, RMI offers comprehensive, cost effective options

When renal artery stenosis is suspected as the cause of poorly controlled hypertension, an imaging evaluation is often critical to diagnosis and treatment planning. However, debate continues within the literature about what test is most effective. Also, be aware of varying insurance coverage guidelines.

RMI's ability to offer comprehensive vascular imaging services in an outpatient setting provides a cost effective option that enables patients to get the tests that best suit their needs.

- **CTA** (computed tomography angiography) is outstanding for definitively identifying or ruling out a stenosis and providing a 3-dimensional image for planning angioplasty and stenting, if warranted.
- **MRA** (magnetic resonance angiography) is excellent for generating 3-dimensional views of renal artery anatomy. MRA is a good choice when there is concern about a patient's lifetime ionizing radiation exposure level.
- **Radionuclide Renography** (a.k.a. Captopril Renogram) images the perfusion of the kidney and estimates the functional significance of a stenosis. This can provide an alternative for patients with elevated BUN and creatinine or decreased GFR.
- **Renal Artery Doppler**, a highly effective screening exam for certain patients, is useful as an initial assessment when renal artery stenosis is suspected.

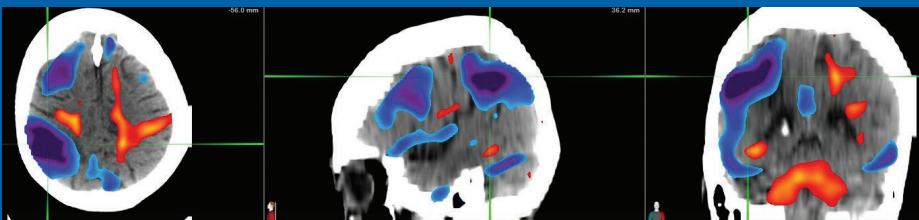
To consult with an RMI radiologist about selecting the test that best fits your patient's medical situation, please call **(810) 732-1919**.

Case Study

HISTORY: 79-year-old with progressive memory loss over the past several years. Some behavioral change with tendency toward anger. No visual hallucinations.

CONCLUSION:

1. Findings most consistent with vasculopathic based dementia with varying degrees of infarct and ametabolic encephalomalacia in right frontal, temporal and parietal lobes, right MCA distribution.
2. Compensatory/reactive hypermetabolic activity in deep white matter bilaterally.
3. No evidence for specific neurodegenerative dementia such as Alzheimer's disease, frontotemporal dementia or DLB.



NEUROPET LEGEND FOR SURFACE RENDERED COLOR CODING

To the left is a surface rendition of cortical metabolic activity referencing normal database with Z-score deviation by region.

GRAY: These areas are within normal range for cortical metabolic activity.

RED/YELLOW: These areas exceed upper normal range of cortical metabolic activity.

BLUE/BLACK: These areas are greater than two Z-scores below normal in metabolic activity. Sulci, fissures, cisterns and ventricles will be depicted here as well.

Community Breast Conference

A Meeting of Medical Minds for Better Breast Cancer Outcomes

The medical community's division into separate institutions and practices can sometimes reduce our ability to draw fully on our collective expertise—unless we actively create opportunities to collaborate for the benefit of patients.

The RMI-hosted Community Breast Conference, in Flint, is one such effort. Area physicians convene bi-weekly to review challenging breast cancer cases. This includes RMI radiologists, colleagues from the area's three major healthcare systems, and independent providers.

The conference brings together the high-level expertise of surgeons, radiologists, medical and radiation oncologists, pathologists, primary care physicians, and other specialists in an effort to analyze each patient's data and formulate a treatment plan for the best possible outcome.

"By sharing knowledge across health systems and practices, we're working toward more uniformity throughout the city in managing breast cancer," said Randy Hicks, M.D. "There's also an educational dimension in terms of looking at the latest research-based evidence to guide best practices. However, the primary focus is always on the care of each patient as we review and discuss each case."

Dr. Hicks encourages physicians to participate by sharing their expertise or presenting cases for review. For more information, please contact Dr. Hicks at **(810) 732-1919**.

Meet

Steve Galliway, PA-C

Interventional Radiology Clinician



A graduate of Wayne State University's Physician Assistant program, Steve Galliway has more than 10 years of experience performing image guided procedures, including Medport/PasPort insertions and removals, dialysis catheter insertions and removals, PICC line access, paracentesis, thoracentesis, and CT and ultrasound guided biopsies and drainages. He is also trained in emergency medicine.

Although relatively new to RMI, Steve has met most of the physicians in the area during his career. This has made him well-suited to the other "hat" he wears in his ongoing role of keeping area medical practices up-to-date on RMI's interventional services.

"When I talk to primary care offices about our ability, in most cases, to provide same-day or next-day service, with minimal waiting time for the patient in a convenient, comfortable setting, it's a real eye opener," he said.

"I've had an office call me at ten minutes to five about a patient who required a PICC line immediately. Even on such short notice, we were able to make it happen. They value knowing that RMI will make that kind of effort for their patients every day."

Medicaid Accepted and Time-of-Service Pricing Available

Approximately one in five Michigan residents depends on Medicaid for healthcare coverage. Given current economic conditions and expected changes to the eligibility threshold, this number is likely to increase even further. Many other patients are uninsured or have limited coverage requiring them to pay out-of-pocket for medical care.

At RMI, we understand how these conditions are impacting both patients and medical practices. So we wanted to ensure that our colleagues know that we accept all payers—including Medicaid and self-pay patients.

In order to provide access to medical services for all, RMI offers payment terms for self-pay patients and discounts for payment at time of service. For details, please contact RMI at **(810) 732-1919**.